

The Transition from Teeth to Implants and the Use of Post-ceramic Soldering

Basil Mizrahi, BDS, MSc, MEd*
Anthony Laurie, RDT, FCGI, FBIDST**

Dental implants have become a widely accepted and successful treatment option for patients who have a failing dentition in which all the teeth in the arch require extraction.¹⁻³

The challenge is to make the transition from teeth to implants as smooth and undisruptive as possible from both esthetic and functional aspects. Since predictability is a key factor in reducing clinician stress levels, this transition is just as important for the clinician as it is for the patient and needs to be carefully planned and managed.

Patients often will not accept or tolerate a removable prosthesis as an interim restoration while the implants are integrating. One way to manage this is to maintain certain teeth deemed for extraction to support a provisional fixed partial denture (FPD) while the implants are integrating. Once the implants have integrated and can be

used to support a prosthesis, the remaining natural teeth are extracted.

This form of treatment is usually reserved for the maxillary arch, where esthetics is important and bone quality may be inferior to that of the anterior mandible. Both of these factors preclude immediate placement and restoration of implants, which is sometimes possible in the mandible.⁴

CASE REPORT

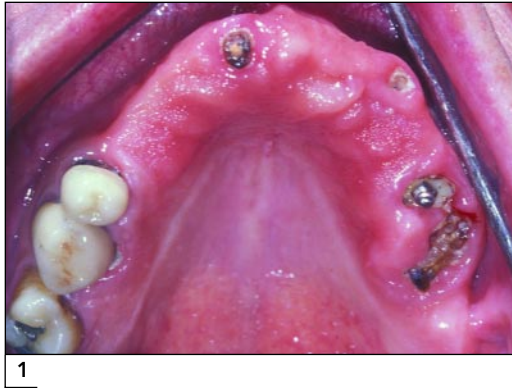The following case describes the transition from teeth to implants in a patient who could not tolerate the partial denture he was wearing (Fig 1). The treatment plan called for an implant-supported complete-arch FPD with extraction of all remaining maxillary teeth. The patient refused to wear any sort of removable prosthesis during treatment.

Prior to treatment, an acrylic provisional FPD was fabricated using a diagnostic waxup. It is often helpful for the technician to add a palatal locator to the provisional FPD to maintain the correct orientation during relining (Fig 2). At the same time, a clear acrylic surgical guide was made to aid in implant placement at a later date (Fig 3).

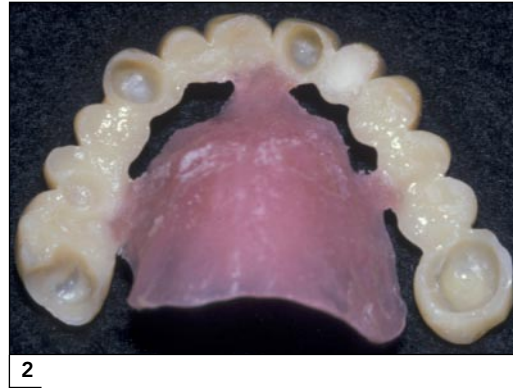
*Clinical Lecturer, Eastman Dental Institute; Specialist in Prosthodontics and Restorative Dentistry, London, England.

**Dental Excellence, London, England.

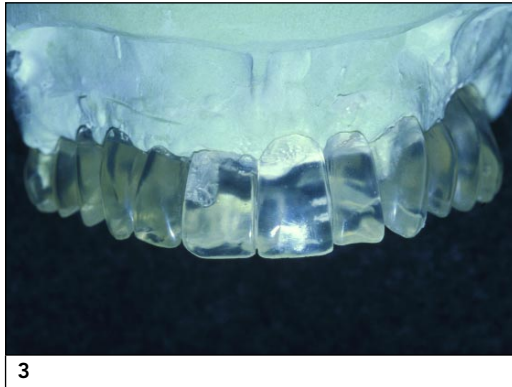Correspondence to: Dr Basil Mizrahi, 39 Harley Street, London W1G 8QH, England. E-mail: basil@mizrahi.freeserve.co.uk
Website: www.basilmizrahi.co.uk



1



2



3

Fig 1 Preoperative view.

Fig 2 Acrylic shell provisional with palatal locator.

Fig 3 Surgical-radiographic guide based on the provisional FPD.

Clinical Protocols

The only anterior supports for the acrylic FPD were two small roots in the areas of the left lateral incisor and right central incisor. All that remained of the left first molar were the three roots. The palatal root was retained, and the remaining two roots were extracted (Fig 4). On the right side, the first molar was retained, and the second premolar and second molar were extracted. The provisional FPD was relined, and the palatal locator was removed (Fig 5).

There were no mandibular posterior teeth, and no forces were generated distal to the premolar area; therefore, a metal-reinforced provisional FPD was not needed. In many cases, however, it is necessary to fabricate a metal-reinforced, acrylic provisional FPD for improved strength and longevity.

Dental implants were placed, and following an integration period of about 6 months, the implants were uncovered and healing abutments placed (Fig 6). At this time, the provisional FPD was cut back to allow room for the healing abut-

ments. Three weeks after the implants were uncovered, an impression was made of the implant heads, and a cast with a soft tissue replica was formed (Fig 7). Abutments were selected using a matrix made on a cast of the provisional restoration as a guide (Figs 8a and 8b). The FPD was waxed up (Fig 9), and a new implant-supported, acrylic provisional FPD was made.

At this stage it was no longer necessary to keep the remaining natural teeth. The anterior teeth were extracted at this stage and the posterior teeth were extracted at a later stage (Fig 10). The selected abutments were screwed into the implants, and the new provisional FPD was fitted onto the implants (Fig 11).

The provisional FPD was refined as needed. After 3 months, once the patient was satisfied with the esthetics and function, the final impression of the implants was made using polyether impression material (Impregum, 3M Espe, Seefeld, Germany) in a custom tray with screw access holes.

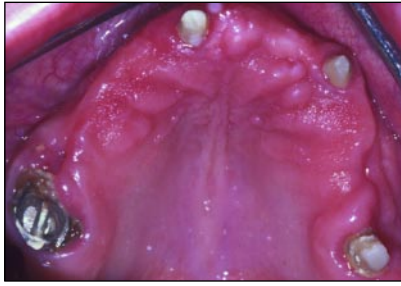


Fig 4 Teeth prepared for the acrylic shell provisional.

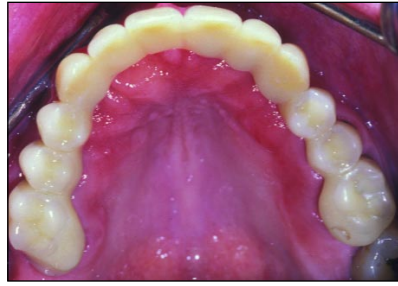

Fig 5 Trimmed acrylic provisional with palatal locator removed.

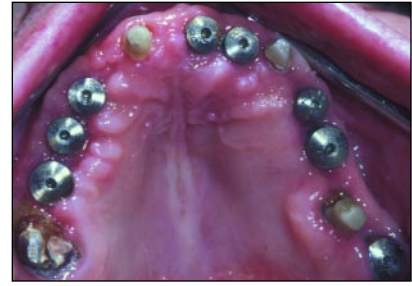

Fig 6 Healing abutments in place after the implants were uncovered.

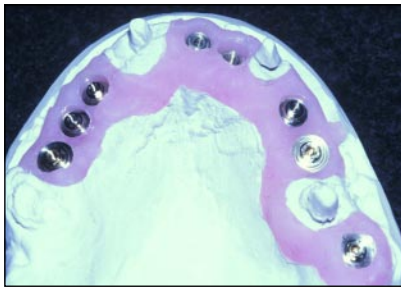


Fig 7 Cast of implants.

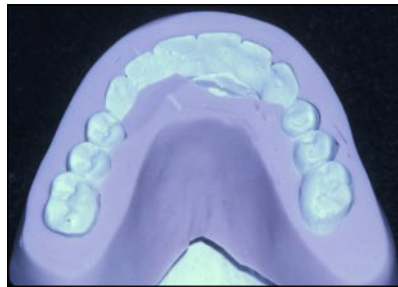


Fig 8a Matrix on the cast of the provisional FPD to aid in abutment selection.

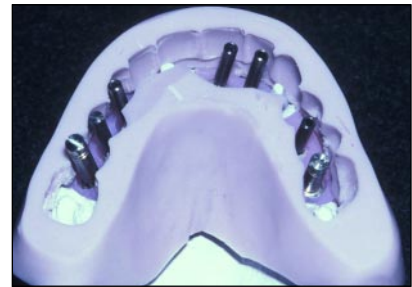

Fig 8b Matrix on the cast of the implants to aid in abutment selection.

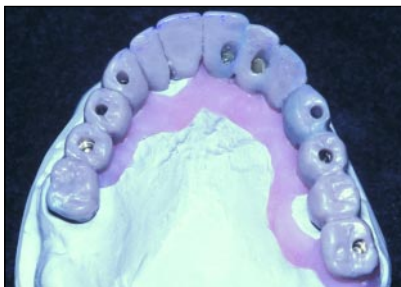

Fig 9 Waxup of the new implant-supported provisional FPD.

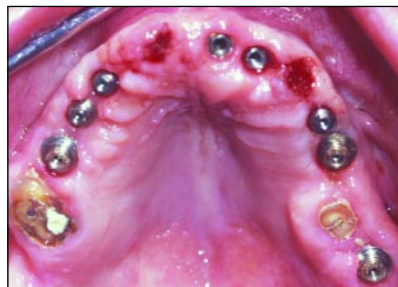

Fig 10 Extraction of abutment teeth and placement of implant abutments.

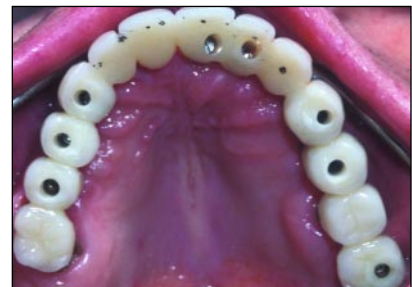

Fig 11 Implant-supported provisional FPD.

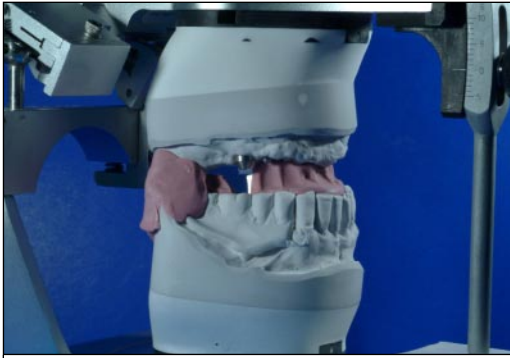Laboratory Protocols

A successful implant-supported reconstruction, which complies with the desired parameters of form, function, fit, esthetics, phonetics, and biocompatibility, requires a team approach. This has become increasingly apparent, as the nature of clinical treatment and the sophistication of restoration have progressed. The key factors to success are communication, provision of appropriate information, and precision of clinical and labo-

ratory procedures. All procedures should be aimed at minimizing distortions.⁵

Prior to fabrication of the definitive restoration, study casts of the maxillary provisional FPD and the mandibular arch were made. These were cross-mounted on an articulator to the maxillary working cast using an intraoral registration.

Silicone indices of the maxillomandibular relationship taken from the study casts of the provisional restorations were used to check the accuracy of the mounting of the working cast (Fig 12). An in-

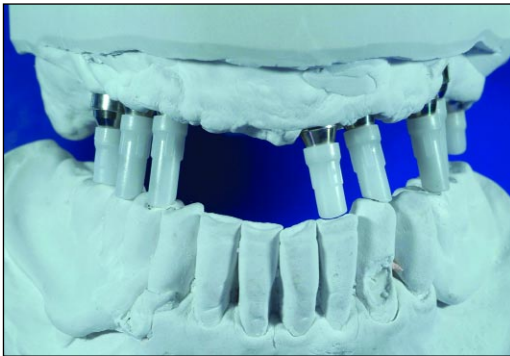


12

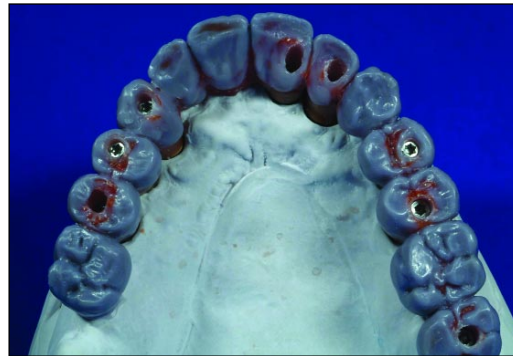Fig 12 Silicone indices for cross mounting of casts.

Fig 13 Plastic sleeves on gold cylinders cut to the correct vertical dimension.

Fig 14 Full-contour waxup.



13



14

cisal guidance table, copying the guidance established in the provisionals, was made to ensure minimal guidance change in the definitive restoration.

The patient visited the laboratory to discuss expectations regarding shape and color before fabrication was begun. The color was determined, in agreement with the patient, by comparing samples of the ceramic to be used in the fabrication process against the natural mandibular incisors. Close-up photographs of the remaining mandibular incisors were taken as a guide to the internal detail and general appearance.

Full-contour Waxup

The gold cylinders were screwed into place on the working cast and their plastic sleeves trimmed

down to size within the set vertical dimension (Fig 13). A Duralay (Reliance Dental Mfg, Worth, IL) acrylic skeleton framework was fabricated, connecting the copings. The framework was made in sections, only connecting each abutment with a small final addition to minimize polymerization shrinkage and to ensure passivity.

The arch was then waxed up to full contour over the acrylic framework (Fig 14). Silicone indices made on the cast of the provisional restoration and the incisal guidance table were used as guides to form and function. Then silicone indices of the full-contour waxup were made and used to check the cutback, thus ensuring optimum support for the veneering porcelain by the metal framework. The indices were also used later as a guide to the ceramic buildup.

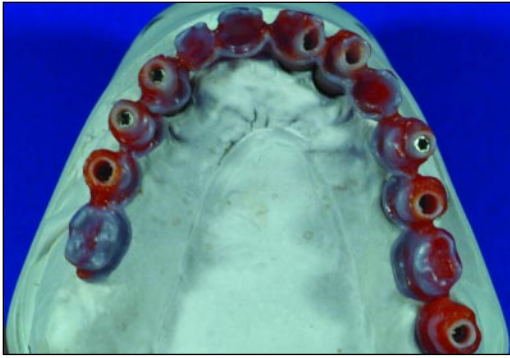


Fig 15 Cutback pattern sectioned and rejoined.

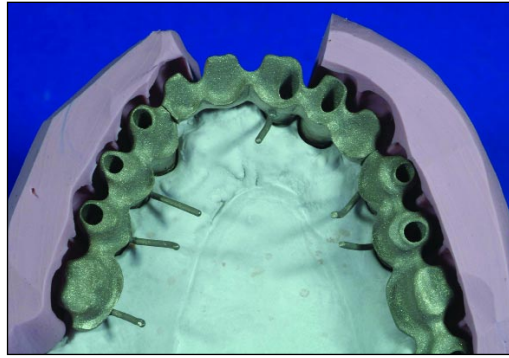


Fig 16 Metal casting checked against silicone indices.

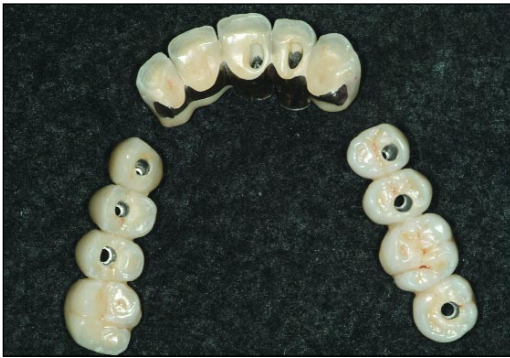

Fig 17 Completed porcelain application to the three separate sections.

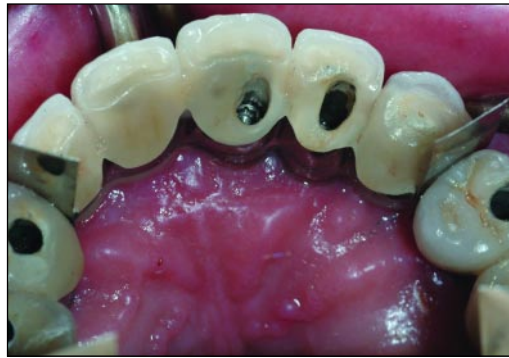

Fig 18 Individual sections with a thin space in between for post-ceramic soldering.

Metal Framework

The pattern for the metal substructure was refined, and each section between abutments was cut and rejoined to ensure passivity (Fig 15). The overall arch was cast in three sections, each less than 35 mm, to ensure a passive fit.⁶

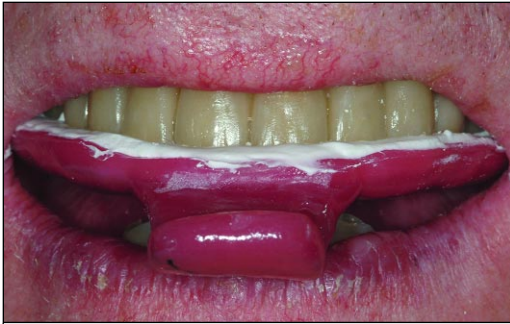The posterior sections were cast first. The anterior section was waxed into contact with the cast sections to ensure an optimum relationship. It was then cast. The cast sections were trimmed and prepared for application of porcelain, their final form being checked against the silicone indices made on the waxup (Fig 16). The metal was airborne-particle abraded with 90- μ m aluminum oxide, steam cleaned, and degassed in a porcelain furnace.

Porcelain Application

The metalwork was opaqued, and the selected shades of porcelain were applied to the biscuit stage using the silicone indices made from the waxup as a guide. The sectioned arch was adjusted on the articulator, and the porcelain was selectively stained and glazed (Fig 17). A custom tray was then fabricated for the intraoral soldering pickup.

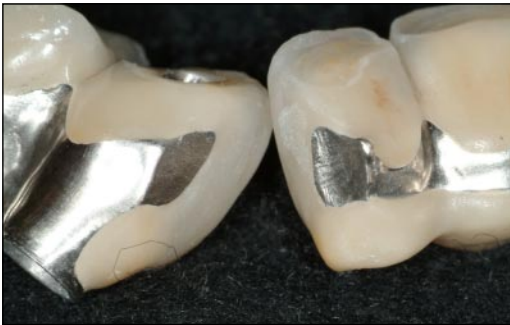Try-in

The three individual sections were tried in the mouth to ensure a passive fit of each section and a thin space between each section (Fig 18). An intraoral soldering pickup index was made using the prefabricated custom tray loaded with an ultralow



19

Fig 19 Intraoral soldering index pickup.



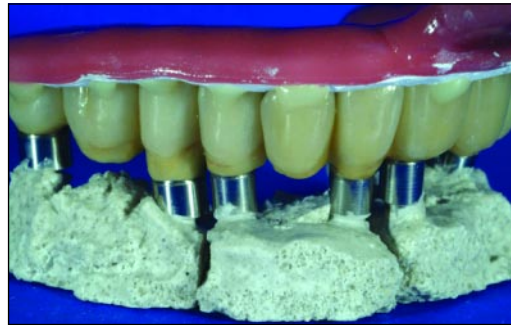20a

Fig 20a [Au: Please provide legend.]

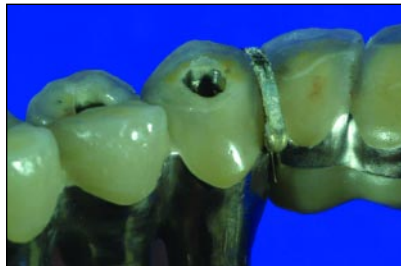Fig 20b Individual sections held in place with sticky wax.[Au: Legend OK?]

Fig 21 Flux and solder applied to joint.

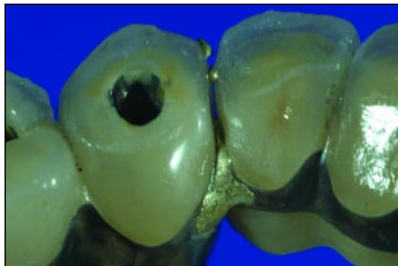Fig 22 After soldering.



20b



21



22

expansion plaster (Gnathostone, Zeus, Roccastrada, Italy) (Fig 19).

After try-in and pickup, the index and sections were returned to the laboratory for soldering.

Post-ceramic Soldering

The sections were checked for passivity and ease of removal from the index, and the joints were cleaned and stoned (Fig 20a). The gap between the surfaces to be soldered was checked to ensure that there was sufficient space (0.3 to 0.5 mm) for the solder to flow. Abutment analogs were screwed into the framework, and sticky wax was used to hold the located sections in the index. The

arch was invested with linear blocks of investment between each joint and with separate supporting blocks as required (Fig 20b). This was to ensure that expansion of the investment during soldering was truly linear between each joint, thus negating any error caused by cross-arch expansion.

The sticky wax was carefully removed with a scalpel to enable easy removal of the pickup index. Flux was applied to the solder joints together with sufficient solder to fill each joint (Fig 21). The arch was carefully placed in a porcelain furnace and soldered in air using 760 solder (U Lot, Heraeus Kulzer, Hanau, Germany) at a temperature up to 810°C to ensure good flow and wetting of the joint (Fig 22). The soldered restoration was allowed to cool and then divested.

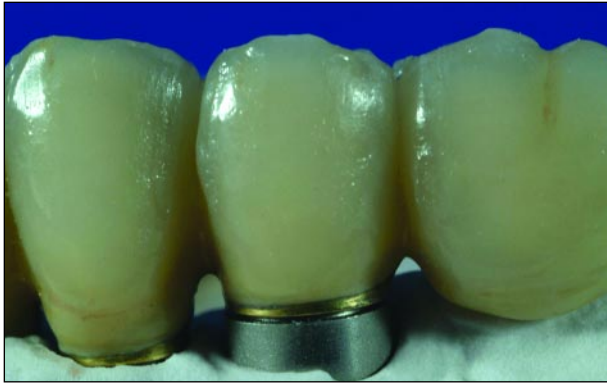

Fig 23 Discrepancy on the master cast after soldering.

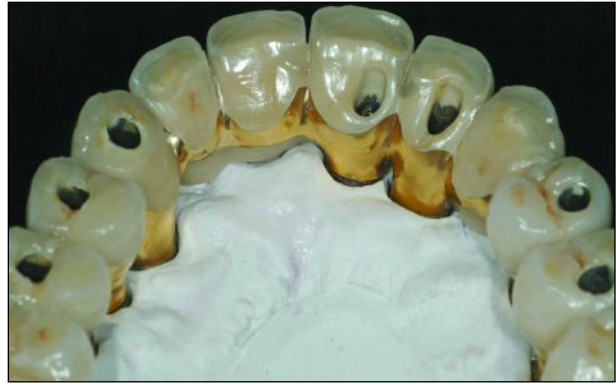
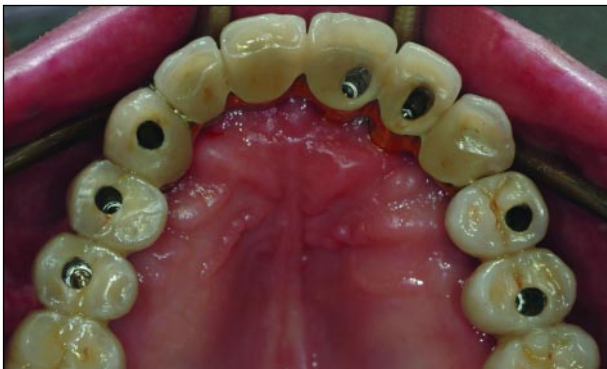
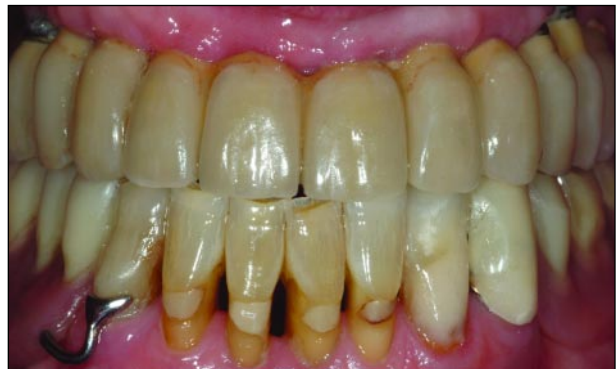Fig 24 Completed FPD with gold-plated metal.

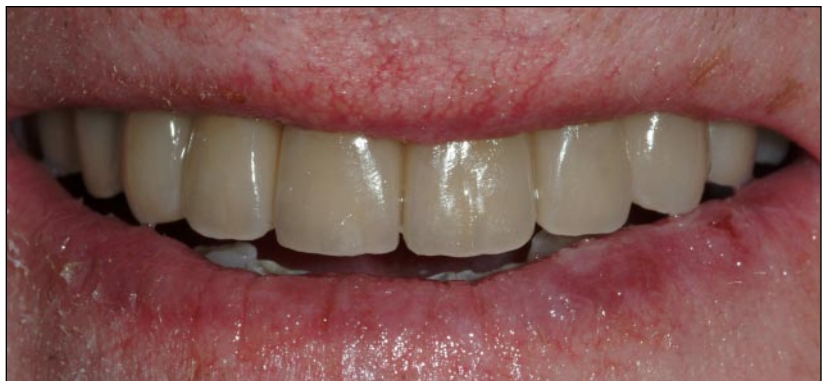

25a



25b

Figs 25a to 25c Postoperative views.



25c

Finishing Process

Passivity of the splinted arch was checked with the index. To demonstrate how an intraoral pickup negates small errors in working cast, the soldered denture was seated back on the original cast but, as expected, showed a slight discrepancy (Fig 23). The FPD was finally polished and the metal gold plated (Fig 24).

Final Delivery

A few days later, the final screw-retained prosthesis was delivered (Figs 25a to 25c). A mandibular partial denture was fabricated for the patient as well.

ACKNOWLEDGMENTS

The authors would like to thank Dr Malcolm Schaller for placement of the implants, Lab 39 for fabrication of the initial acrylic provisionals, and Richard O'Brien of Dental Excellence for the definitive metal and porcelain work.

REFERENCES

1. Rodriguez AM, Orenstein IH, Morris HF, Ochi S. Survival of various implant-supported prosthesis designs following 36 months of clinical function. *Ann Periodontol* 2000;5:101–108.
2. Zitzmann NU, Marinello CP. Treatment outcomes of fixed or removable implant-supported prostheses in the edentulous maxilla. Part II: Clinical findings. *J Prosthet Dent* 2000;83:434–442.
3. Lundqvist S, Carlsson GE. Maxillary fixed prostheses on osseointegrated dental implants. *J Prosthet Dent* 1983;50:262–270.
4. Ericsson I, Randow K, Nilner K, Peterson A. Early functional loading of Brånemark dental implants: 5-year clinical follow-up study. *Clin Implant Dent Relat Res* 2000;2:70–77.
5. Tan KB, Rubenstein JE, Nicholls JI, Yuodelis RA. Three-dimensional analysis of the casting accuracy of one-piece, osseointegrated implant-retained prostheses. *Int J Prosthodont* 1993;6:346–363.
6. Wise M. Fit of implant-supported fixed prostheses fabricated on master casts made from a dental stone and a dental plaster. *J Prosthet Dent* 2001;86:532–538.