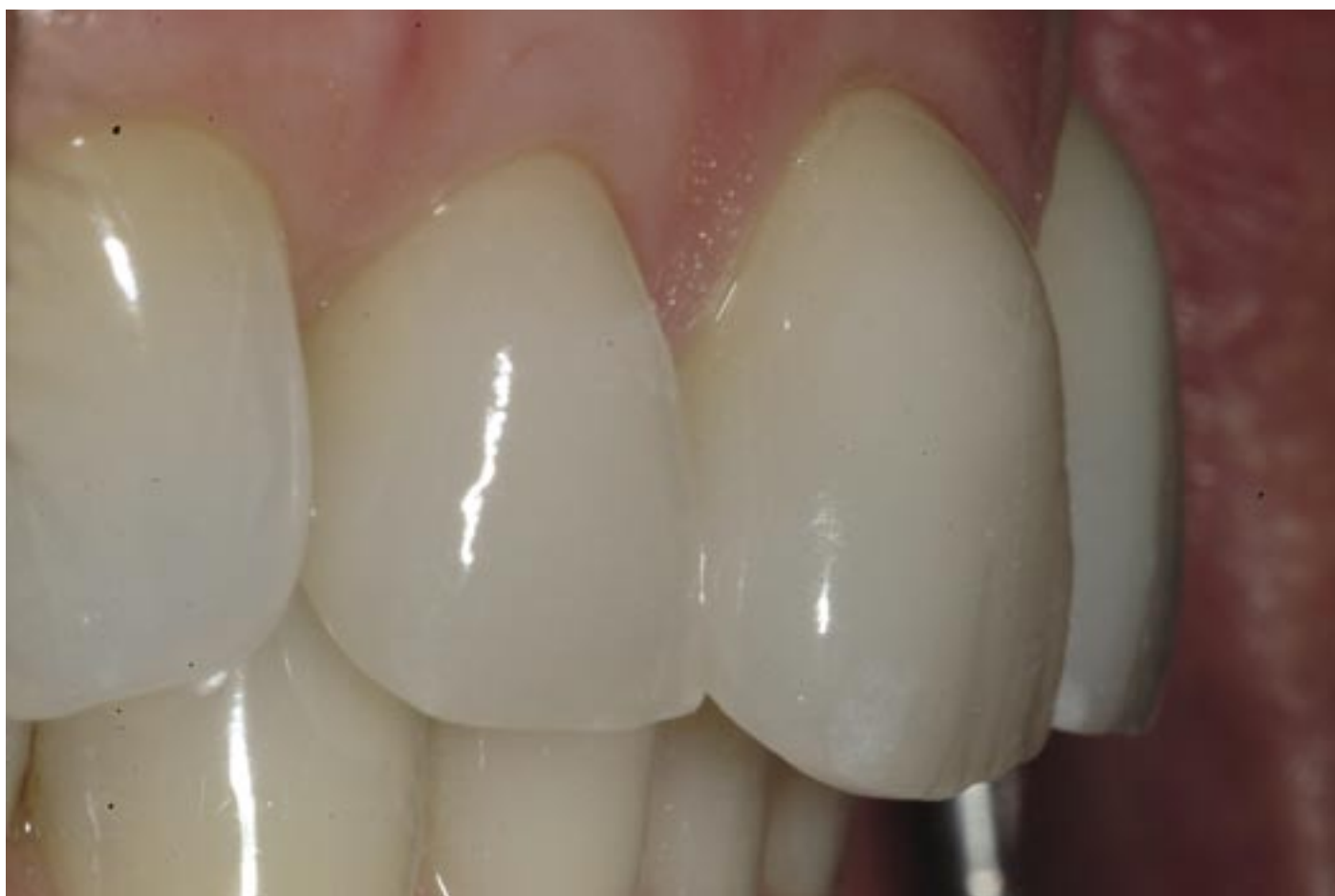

# Porcelain veneers: techniques and precautions

Basil Mizrahi looks at a case involving the restoration of four teeth with porcelain veneers and examines adjunctive procedures to improve their prognosis



Dr Basil Mizrahi graduated as a dentist from the University of the Witwatersrand, South Africa in 1989. In 1993, he obtained an MSc in Dentistry at the University of the Witwatersrand majoring in Periodontics. After five years in general practice, he moved to the USA to specialise in Prosthodontics at Louisiana State University (LSU), School of Dentistry. In June 1998, Basil graduated from a three-year full time Prosthodontic program at LSU under the leadership of Dr Gerard Chiche a world leader on anterior aesthetics. Basil is registered as a Specialist in Restorative Dentistry and runs a full time, referral practice in London's West End. He runs hands-on courses in 'Advanced Restorative and Aesthetic Dentistry' and is a Clinical Lecturer at UCL, Eastman Dental Institute.

## Abstract

This article describes the restoration of four upper anterior teeth with porcelain veneers. Because such treatment is usually elective, all precautions should be taken to ensure treatment is as conservative as possible. It may also be necessary to carry out non-restorative adjunctive procedures to create a favourable environment and improve the long-term prognosis of the veneers. Porcelain is extremely fragile and complications such as post bonding fracture may occur. If and when this does happen the clinician should be aware of the possible cause and how to deal with the situation.

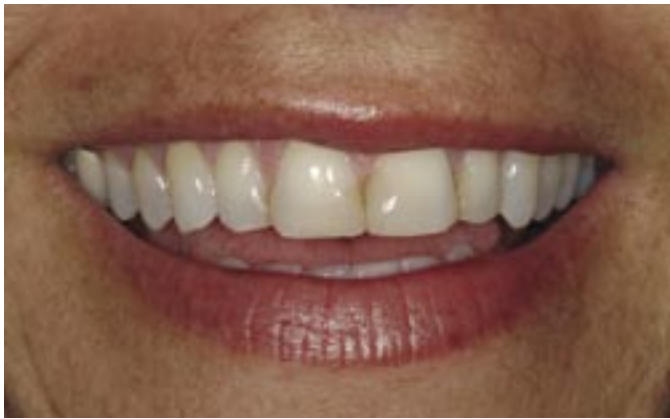

Figure 1: Pre-op smile

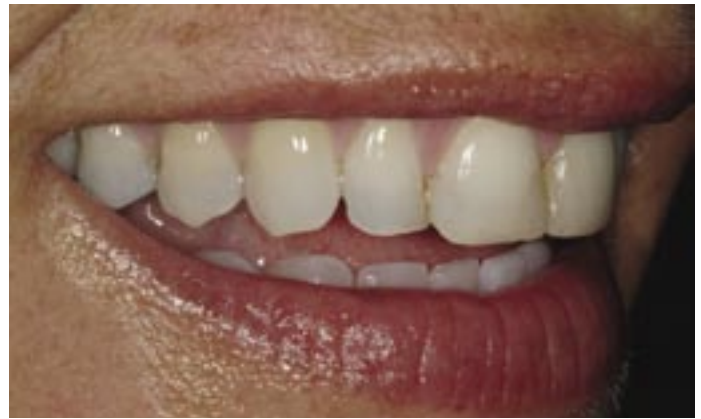

Figure 2: Pre-op smile

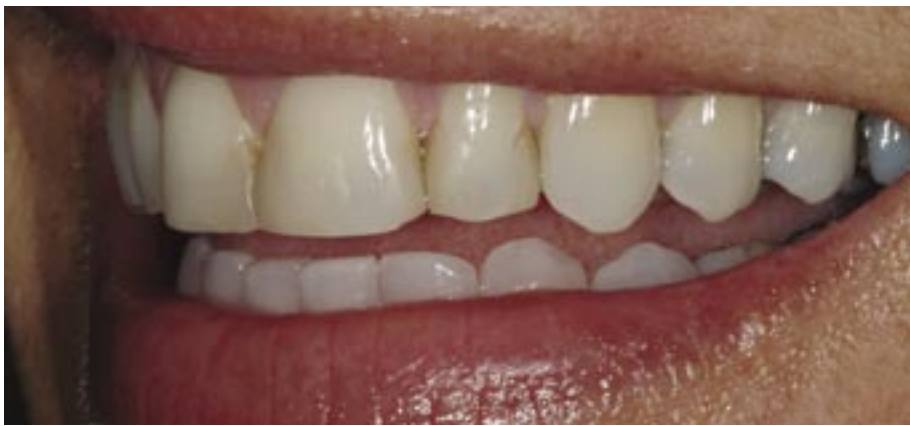

Figure 3: Pre-op smile

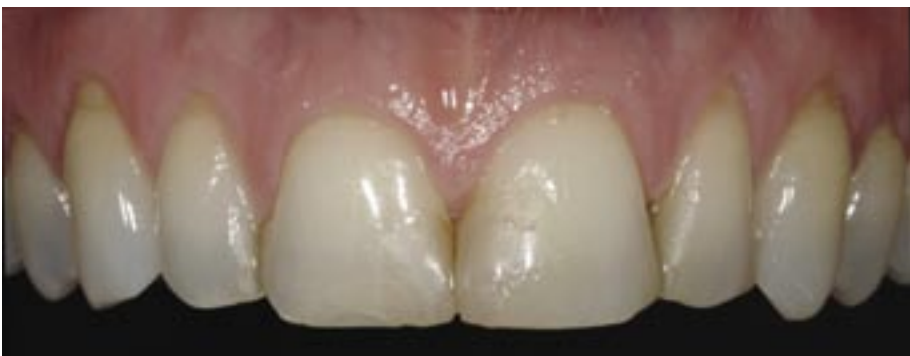

Figure 4: Gingival recession with exposed dentine. Note the large interproximal composite restorations on the four incisors

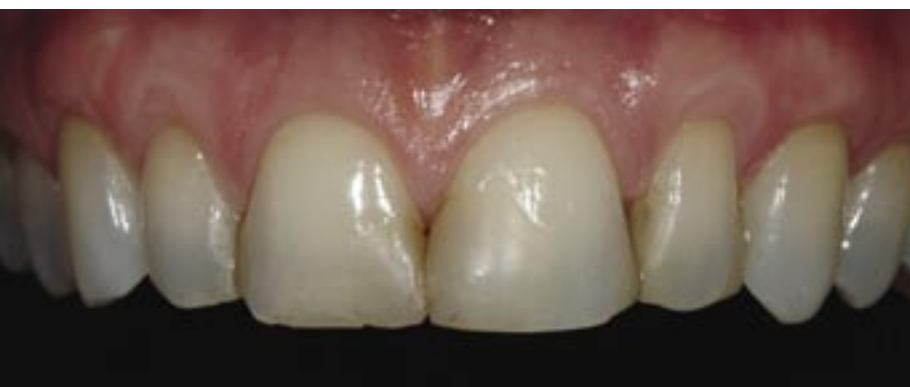

Figure 5: Post –periodontal surgery with root coverage (Dr Jonathan Lack)

## Clinical relevance

Careful case assessment, adjunctive treatment and precise clinical and laboratory techniques are important aspects to ensure optimal longevity and aesthetics of porcelain veneers. Despite all precautions, post treatment complications can occur.

## Objectives

The reader should understand the importance of creating a favourable environment for treatment with porcelain veneers and the techniques involved in actual treatment.

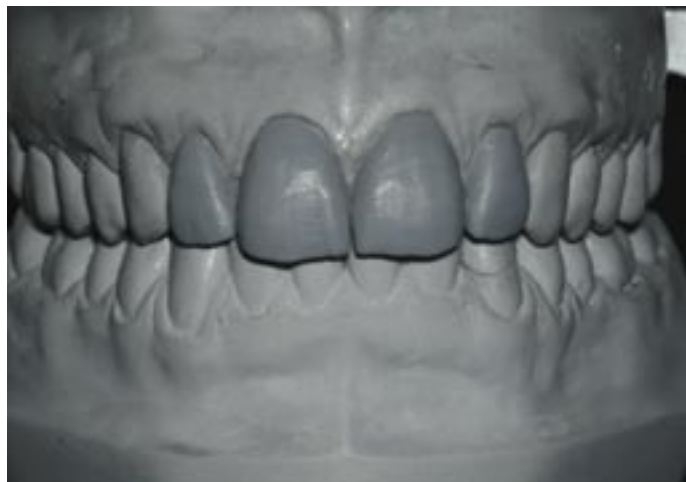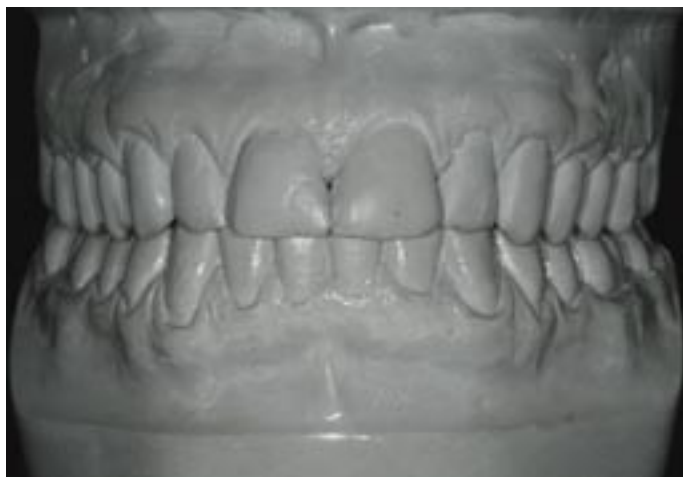Used with the correct indications, porcelain veneers represent a relatively conservative treatment modality with the potential for an excellent aesthetic outcome and good longevity (Friedman, 1998, Dumfahrt and Schaffer, 2000, Peumans et al, 2004). Most veneers are placed for cosmetic reasons and are therefore elective. For this reason it is imperative to ensure minimal tooth destruction and attempt to achieve maximum restoration longevity. This requires careful case selection, treatment planning and precision in all clinical and laboratory stages.

In thin sections, porcelain is a fragile and unforgiving material and despite taking precautions, complications may still occur during treatment with porcelain veneers. The following case details the technique involved in restoring the maxillary incisor teeth with porcelain veneers and illustrates a post treatment complication that may arise.

## Case report

The patient presented complaining about the poor appearance of her upper front teeth. Her incisors had been restored numerous times with direct composite resin to treat interproximal decay as well as to close the interdental spaces.

On examination the following findings were noted (Figures 1-4) :



Figures 6a and b Original study casts compared to diagnostic wax-up

- Wear of the central incisor edges creating a flat anterior occlusal plane
  - Discolouration and marginal staining of the existing composite restorations.
  - Gingival recession around the necks of lateral incisor, canine and first premolar teeth.
- The combination of the worn incisal edges

and increased width of the upper incisors due to the composite bonding, detracted from the smile in two aspects.

1. The length to width ratio of the central incisors was too small, making the teeth appear too square. According to Chiche and others a pleasing proportion is 80% (Chiche and

Pinault, 1994, Magne et al, 2003).

2. The incisal edges of the central incisors were a similar length to those of the lateral incisors, creating a flat smile line. A more attractive appearance is obtained when the incisal edges of the central incisors are longer than those of the lateral incisors and the smile line

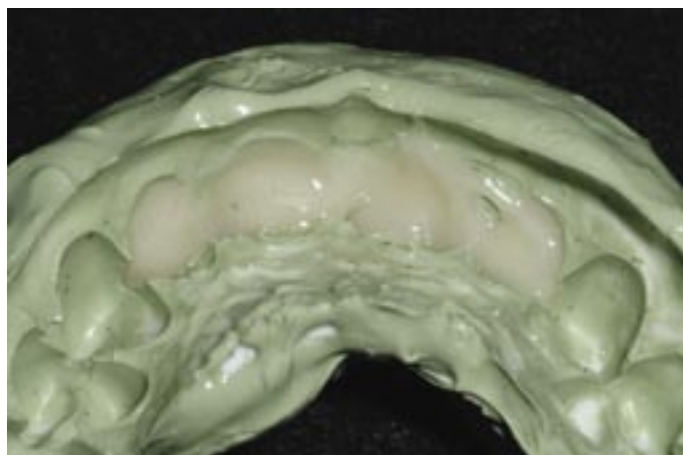

Figure 7: Bis-acryl resin in silicone matrix

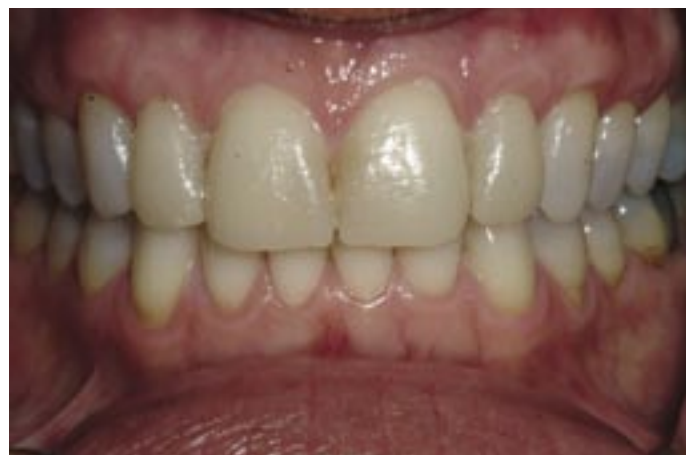

Figure 8: Bis-acryl mock up on teeth

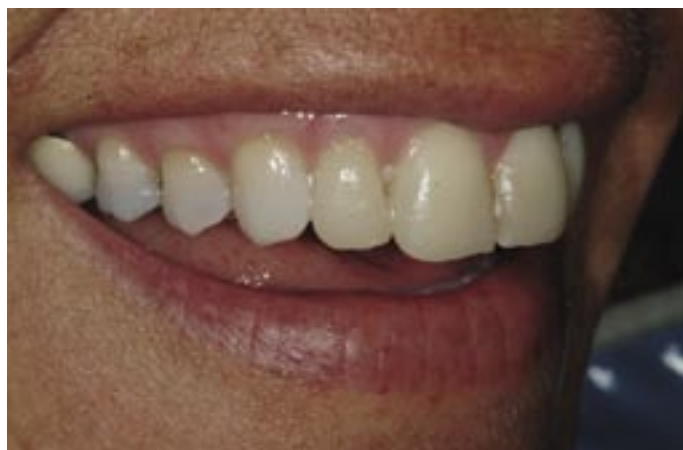

Figure 9: Bis-acryl mock up on teeth

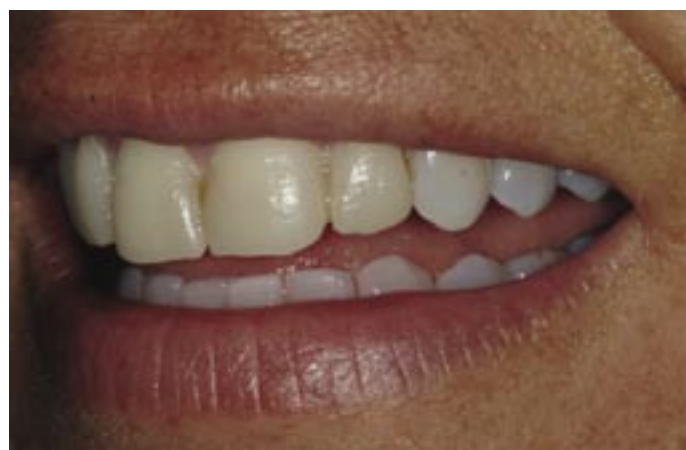

Figure 10: Bis-acryl mock up on teeth

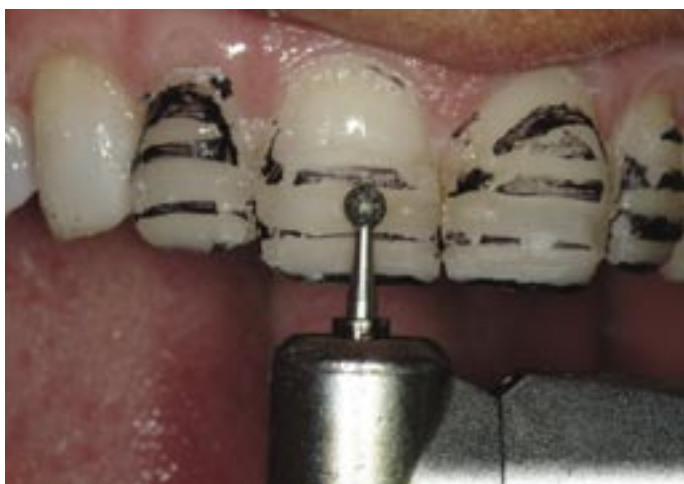

Figure 11: Use of depth cutting burs through Bis-acryl mock up

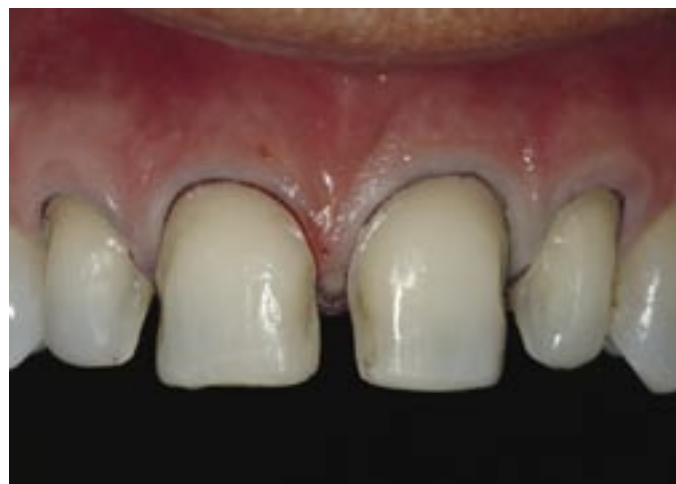

Figure 12: Final preparations with single retraction cord ready for final impression

forms an arc in harmony with the curvature of the lower lip (Sarver, 2001, Fradeani, 2004).

It was decided that porcelain veneers would be the optimal solution to deal with the restorative and aesthetic concerns. At this early stage, it was not possible to determine whether four or six veneers would be needed and this decision was delayed until a diagnostic wax-up had been carried out.

A potential complicating factor for porcelain veneers was the fact that the gingival recession meant that the cervical margin of the veneers would be on dentine (Figure 4), since it has been shown that veneers with their margins in enamel are more successful than those in dentine (Tjan et al, 1989, Lacy et al 1992, Ibaura et al 2007, Dumfahrt 2000, Friedman 1998).

Two options were available to address this issue:

- Place the veneer margins on enamel i.e. about 2-3mm supragingival. This would have the potential to create an aesthetic compromise at the marginal interface due to a potential colour mismatch and the discolouration of the margin over time.
- Carry out mucogingival periodontal surgery to cover the exposed root surface. This would allow the margin of the veneer to be placed on enamel at an equigingival level.

After discussing both options with the patient it was decided to carry out a root coverage procedures on the upper canine and lateral incisors. Following the mucogingival surgery, the gingivae were allowed to mature for about four months before the restorative phase of treatment was begun (Wise 1985) (Figure 5).

## Visualisation

In aesthetic treatment, it is important to start visualising the final result as early as possible

and to continue this visualisation throughout treatment. This ensures that all parties involved in the treatment have the same endpoint in mind and allows changes to be made prior to the final restorations being cemented (Mizrahi, 2005).

The first step in this visualisation process is the diagnostic wax-up (Figure 6). This wax-up should be highly indicative of the final result and it is important to verify that it corresponds to the intended outcome of both the dentist and the patient. The key element of porcelain veneers is the preservation of existing enamel. Over the years, in the adult dentition, erosion and surface wear contribute to the thinning of the existing enamel. When determining the final contour of the wax-up, the technician should seek to replace this lost enamel by bulking out the tooth slightly wherever possi-

ble. This has a two-fold effect of strengthening the remaining tooth and allowing for preservation of existing enamel (Magne and Douglas 1999).

From the wax-up, it was determined that only four veneers would be required. The wax-up was used to fabricate a series of silicone matrices which would later be used for making an intra-oral diagnostic mock-up, a tooth preparation guide and the temporary veneers.

An intra-oral mock up of the final proposed result was made using a Bis-acryl resin temporary resin material (PreVISION CB, Hereaus Kulzer) in a silicone matrix (Figure 7). Once the resin had polymerised, the matrix was removed and an aesthetic and functional analysis was made of the result (Gurel and Bichacho, 2006) (Figures 8-10).

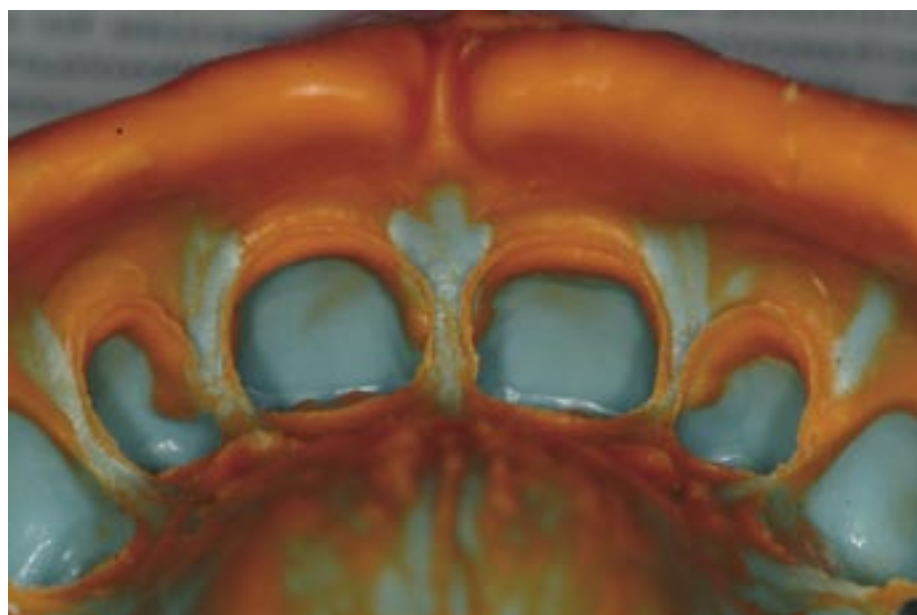


Figure 13: Polyvinyl siloxane impression

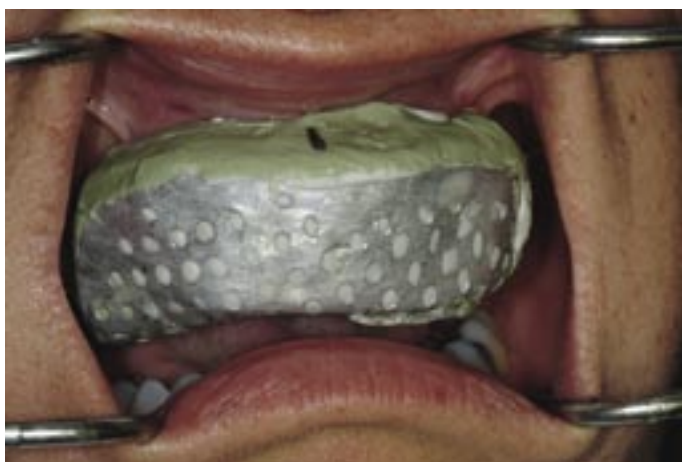

Figure 14: Silicone matrix in place for fabrication of temporary veneers from Bis-acryl resin

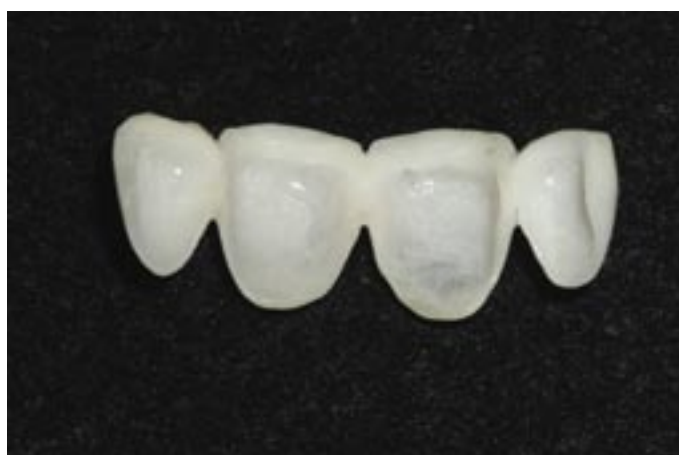

Figure 15: Bis-acryl temporaries with margins refined/relined with methylmethacrylate acrylic resin.

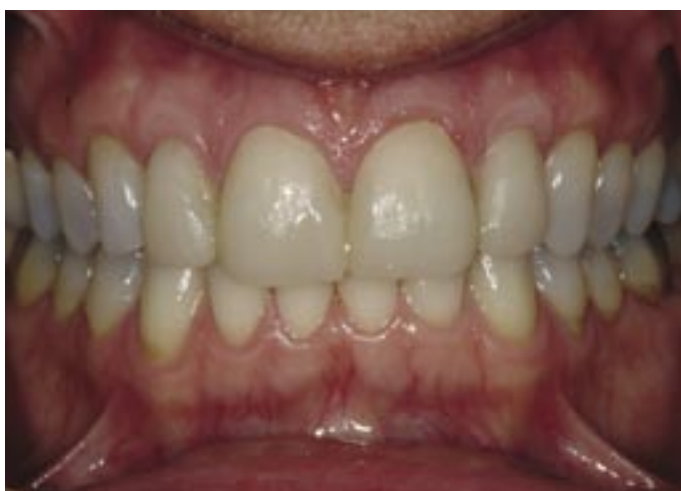

Figure 16: Temporary veneers cemented into place.

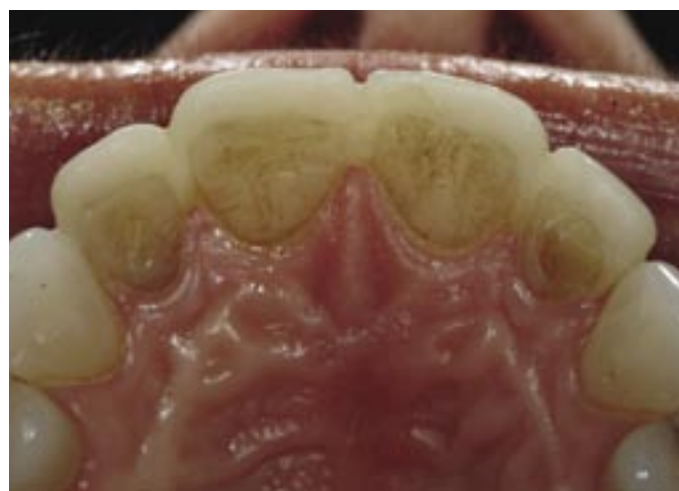

Figure 17: Temporary veneers mechanically locked in place after cementation with methylmethacrylate acrylic resin

## Tooth preparation

Various techniques for accurate tooth reduction have been proposed, including silicone matrices, freehand preparation and depth limiting burs (Cherukara et al, 2005). It is important that whatever tooth reduction guide method is used, it is based on the definitive wax up and not the original tooth. Failure to do this may result in excessive and unnecessary removal of tooth enamel.

In this case depth limiting burs were used to prepare directly through the bis-acryl mockup, as described by Gurel (2003) (Figure 11). The teeth were prepared with a marginal chamfer labially and interproximally, and a butt fit margin palato-incisally with no wrap around onto the palatal aspect (Castelnuovo et al, 2000, Magne and Douglas, 1999) (Figure 12). Contact points were not preserved as the teeth had natural diastema between them. This also allowed for the changing of the tooth widths in the final restorations.

Following tooth preparation, the final im-

pression was made. Even though the preparation margins were at the level of the gingival margins, a retraction cord was used to allow an impression of the tooth surface beyond the margins to be captured (Figure 12). This ensures accurate and complete capture of the entire margin and aids the dental technician in obtaining the correct cervical profile for the restorations. An impression was taken using a well-designed custom tray and a single stage impression technique. Polyvinyl siloxane impression material was used, with heavy body material placed in the tray and light bodied material syringed around the teeth (Figure 13).

## Temporisation

The temporary veneers were made using a bis-acryl temporary resin. Because teeth prepared for veneers are designed to have minimal to no mechanical retention, retaining temporary veneers is a problem. Many techniques advocate allowing the temporary material to cure

on the teeth and lock into undercut/retentive areas such as the interproximal embrasures and incisal overlaps. The excess flash is then carefully trimmed away with a scalpel. The temporary veneers are then broken off at the time of cementation.

It is the author's opinion that it is not possible to accurately trim, verify and refine the margin of the temporary veneers while they remain in place on the teeth. Failure to do this may lead to gingival inflammation, which could complicate and compromise the final cementation. In addition, the fact that there is no layer of temporary cement may allow ingress of bacteria, which may stain the underlying teeth or cause tooth sensitivity. This becomes a more significant problem when the delay between taking the impression and fitting the final veneers is more than one to two weeks. Another potential problem with this technique is that any modification to the shape of the temporary veneers and final polishing must be made intra-orally.

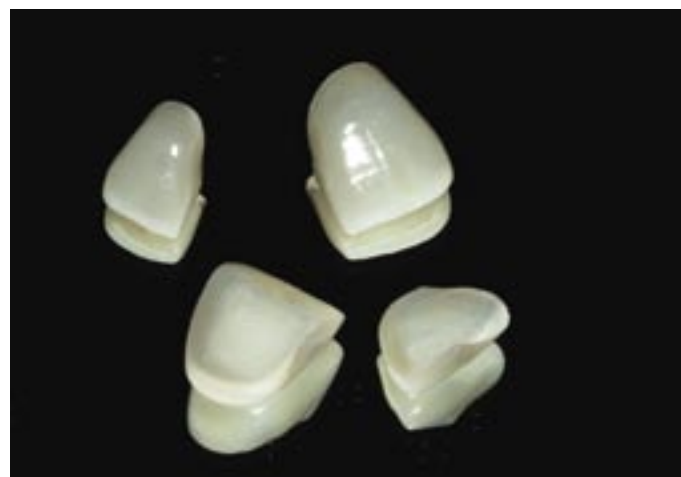
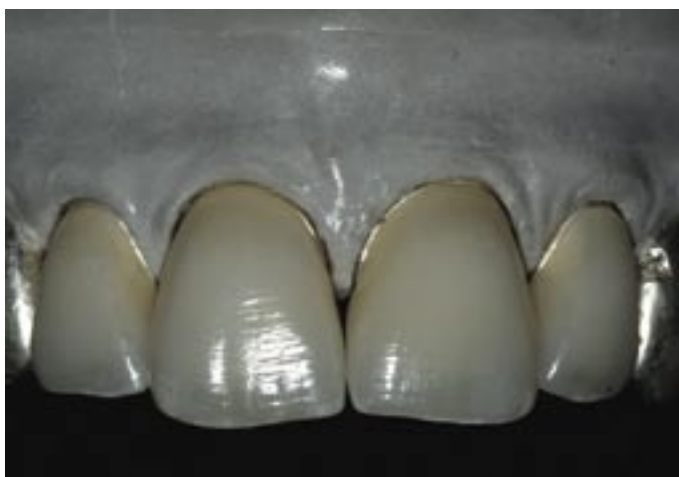
Figure 18: Final veneers. Note detailed, natural morphology, texture and characterisation

Figure 19: Final veneers. Note detailed morphology, texture and characterisation

The author modifies the technique slightly by removing the temporary veneers carefully after they have polymerised on the teeth. This is carried out using a scalpel to remove excess material as described earlier. In addition, any material that has engaged retentive/undercut areas around the teeth is also removed. Once all the retentive areas of the temporary material has been removed, the temporary no longer has mechanical retention and can be gently removed. Where necessary, the margins are relined/refined with a methylmethacrylate acrylic resin, which is more versatile for marginal relining than bisacryl resin (Figures 14-16). The temporary veneers are then cemented in place with a clear temporary cement

(Temp Bond Clear, Kerr). The excess cement is cleaned away and then small amounts of the acrylic resin are applied to the palatal, interproximal and incisal aspects to once again lock the temporaries into place mechanically and augment the retention provided by the temporary cement (Figure 17).

In the laboratory, the veneers were fabricated from feldspathic porcelain. This allows incorporation of multiple shades and characterisations into the porcelain while maintaining minimal thickness (Figures 18 and 19).

At the time of cementation, the temporary veneers were removed from the teeth by removing the palatal/incisal acrylic resin mechanical locks with a sharp instrument.

The teeth were cleaned with pumice and the veneers were tried in. Contact points were adjusted and the marginal precision and fit were checked.

### Veneer surface preparation

After the veneers had been tried in they were cleaned with alcohol and then the following regime for preparing the fitting surface of the veneers was carried out as described by (Magne et al, 2006).

The internal surface of the porcelain veneers were etched for 90 seconds with 9% Hydrofluoric Acid (Figure 20). Hydrofluoric etching generates a significant amount of crystalline debris that contaminates the porcelain

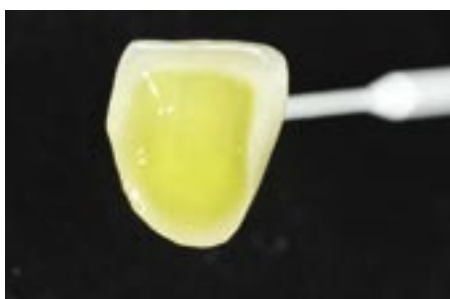

Figure 20: Hydrofluoric acid (9%) etching internal surface of veneer



Figure 21: Clean frosty appearance of well etched porcelain

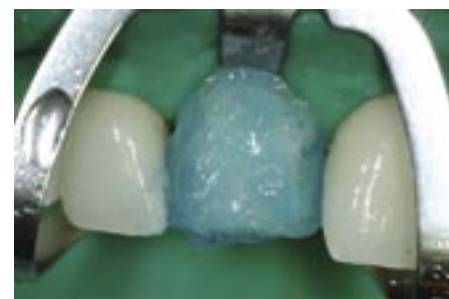

Figure 22: Phosphoric acid (36%) etching of enamel

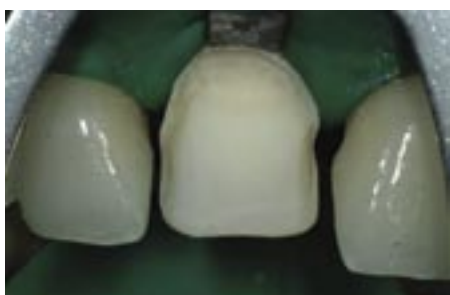

Figure 23: Clean frosty appearance of well etched enamel

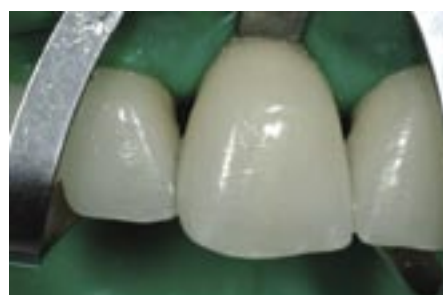

Figure 24: Bonded veneer in place. Note excellent visibility of margin due to rubber dam retraction.

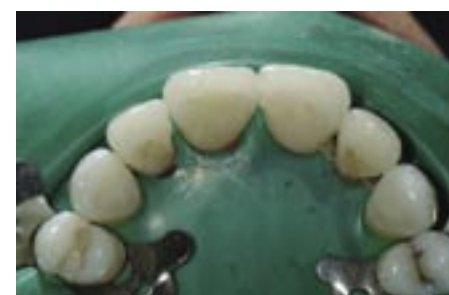

Figure 25: Palatal fit of porcelain veneers

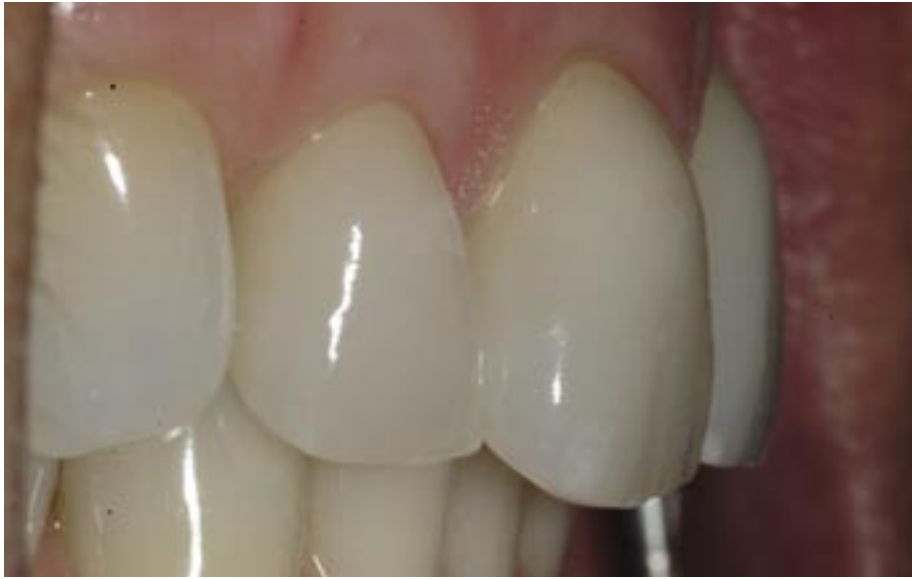

Figure 26: Final veneers bonded in place

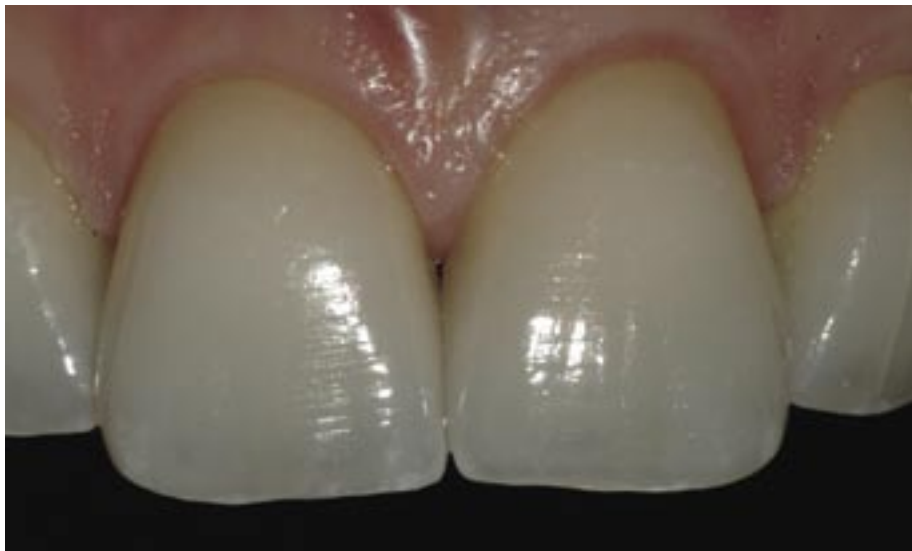

Figure 27: Final veneers bonded in place

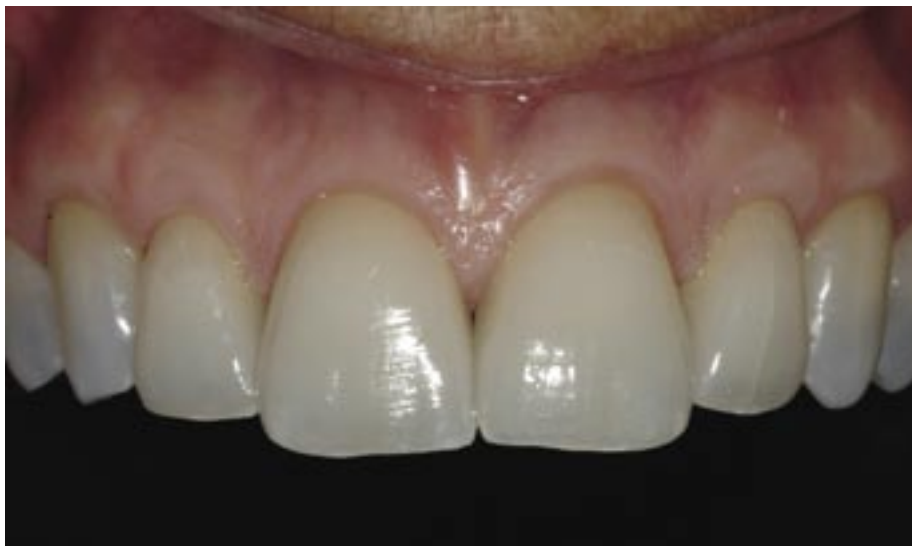

Figure 28: Final veneers bonded in place

surface and may reduce bond strength by 50%. To remove this debris, the veneers were rinsed with water for 20 seconds, then cleaned with 37% Phosphoric acid (gentle brushing with microbrush for a minute), re-rinsed with water for 20 seconds and then finally immersed in 95% alcohol in ultrasonic bath for five minutes. Following this protocol the veneer surface should appear clean and have a similar appearance to etched enamel (Figure 21). Silane coupling agent is then applied and if possible, dried well with warm air (Filho, 2004, Barghi, 2000, Shen et al, 2004).

Whenever possible, cementation should be carried out under rubber dam one tooth at a time. The advantages of improved visual and instrument access and moisture control far outweighs the disadvantage of the increased time needed. The clamp used is a butterfly style clamp with care taken to ensure the jaws of the clamps are stabilised on the tooth surface and not the gingivae (Figure 22). Warm impression compound can be used to stabilise the clamp on the adjacent teeth if necessary.

The veneers were cemented in place with a light cured veneer luting resin cement (Rely X veneer cement, 3M ESPE). With rubber dam retraction of the gingivae, excess resin cement can be easily removed prior to polymerisation. This eliminates the need for damaging rotary instrument finishing/polishing of the tooth - veneer interface (Figures 23-25). Together with precision in marginal fit, this technique will ensure excellent marginal integrity and a healthy tissue response (Figures 26- 28).

At completion of cementation, a successful result was obtained and both clinician and patient were extremely satisfied (Figures 29-31).

## Post operative crack

When the postoperative photos were viewed, it was apparent that a vertical crack was present in the lateral incisor. This was not noticed by either patient or dentist at the time of cementation and seemed to be made apparent by the camera flash. The patient was recalled and the crack was pointed to her on the photos. Even at this time, despite the knowledge of the crack it was not noticeable with direct vision and as such, it was decided to leave the veneer in place.

Magne et al (1999) have proposed that a possible cause of this is a ceramic to luting composite thickness ratio of above 3:1. When this ratio is large, the forces created by the polymerisation shrinkage of the luting cement may cause fracture of the thin porcelain veneer. Post bonding cracks are an acknowledged, albeit rare, complication of porcelain veneers. Based on literature it appears that if the veneer

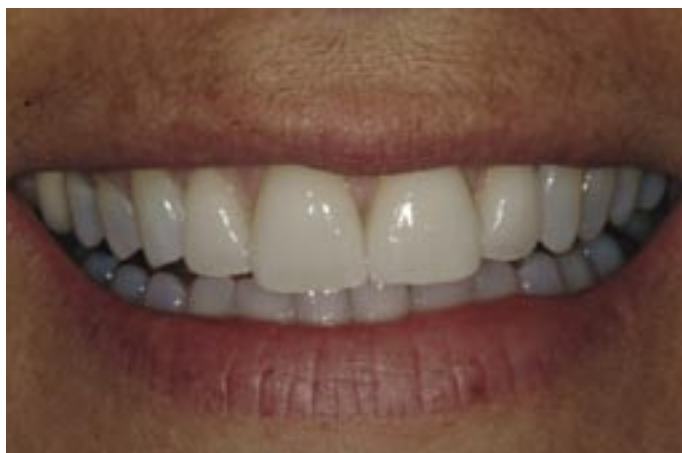

Figure 29: Post op appearance of smile

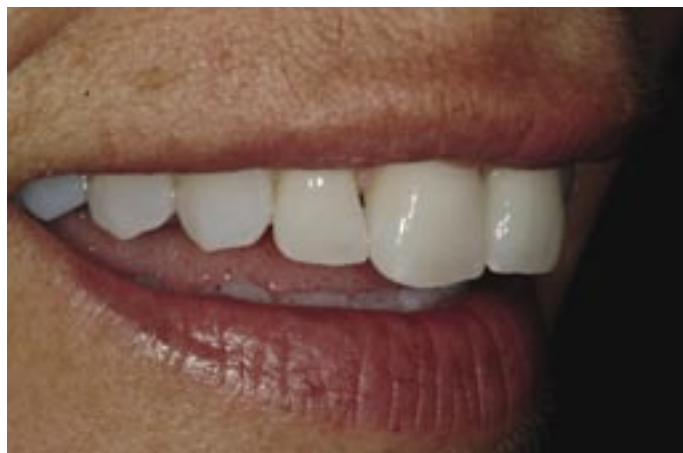

Figure 30: Post op appearance of smile

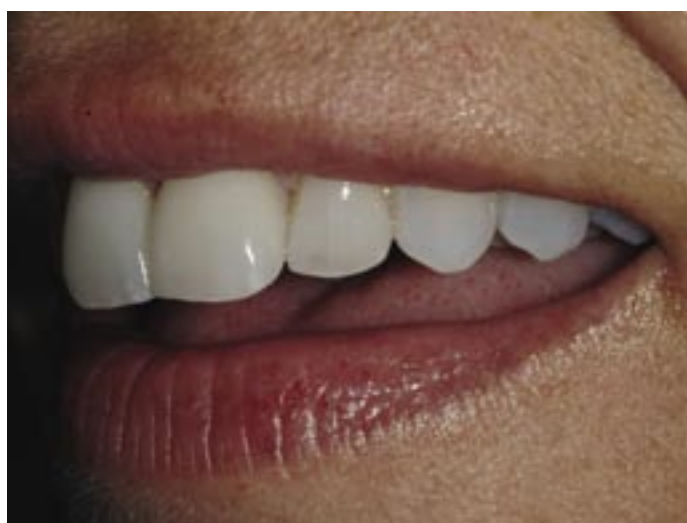

Figure 31: Post op appearance of smile.

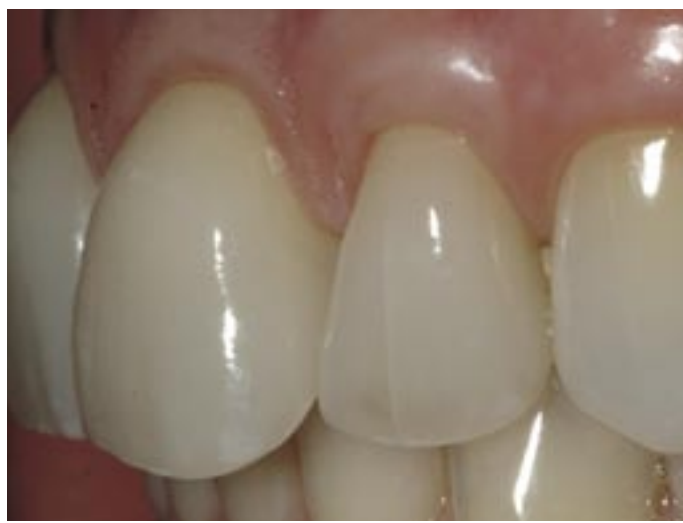

Figure 32: Post-bonding crack on left lateral incisor

is well bonded onto the underlying enamel a post bonding cracks does not jeopardise the longevity of the veneer and if the crack is not an aesthetic concern, the veneer should be left in place (Barghi and Berry, 1997). If the crack is obvious and detracts from the appearance, it is then necessary to remove and remake the veneer.

## Discussion

Porcelain veneers have been shown to be a good conservative and aesthetic treatment option. However they do have limitations and it has been shown that lack of enamel is one of the main causes of failure. Before treating a patient with porcelain veneers, the favourability of the environment should be assessed. If this is not favourable and margins will be on dentine or if excessive enamel will need to be removed, then alternative/adjunctive treatment options should be considered eg orthodontics and or periodontics.

It is important to follow correct treatment protocols and strive for clinical and laboratory

precision. This ensures minimal damage to tooth and gingivae and ensures optimal long-term prognosis.

Despite following all precautions, because of the delicate nature of porcelain veneers, a possible post-operative complication is cracking. If the veneer has been well bonded to the underlying enamel and is not an aesthetic concern, the patient should be informed and the veneer should be left in place. **A**

## Acknowledgement

Dr Jonathan Lack, Specialist Periodontist, London, England for the periodontal surgery results shown in Figure 5.

Mr Salvatore Sgro, L'Eccellenza Odontotecnica, Rome, Italy, for the excellent technical work.

## References

Barghi N, Berry TG. Post-bonding crack formation in porcelain veneers. *J Esthet Dent*. 1997;9(2):51-4.  
Barghi N. To silanate or not to silanate: mak-

ing a clinical decision. *Compend Contin Educ Dent*. 2000 Aug;21(8):659-62, 664

Castelnuovo J, Tjan AH, Phillips K, et al. Fracture load and mode of failure of ceramic veneers with different preparations. *J Prosthet Dent*. 2000 Feb;83(2):171-80.

Cherukara GP, Davis GR, Seymour KG, et al. Dentin exposure in tooth preparations for porcelain veneers: a pilot study. *J Prosthet Dent*. 2005 Nov;94(5):414-20.

Chiche, G and Pinault A. *Esthetics of Fixed Anterior Prosthodontics*, Quintessence Publishing, Chapter 3, 1994.

Dumfahrt H, Schaffer H. Porcelain laminate veneers. A retrospective evaluation after 1 to 10 years of service: Part II--Clinical results. *Int J Prosthodont*. 2000 Jan-Feb;13(1):9-18.

Dumfahrt H. Porcelain laminate veneers. A retrospective evaluation after 1 to 10 years of service: Part II--Clinical results. *Int J Prosthodont* 2000;13:9-18

Filho AM, Vieira LC, Araujo E, Monteiro Junior S. Effect of different ceramic surface treatments on resin microtensile bond strength. *J*



- Prosthodont. 2004 Mar;13(1):28-35.
- Fradeani, M. Esthetic Rehabilitation in Fixed Prosthodontics. Quintessence Publishing, Chapter 3, 2004
- Friedman MJ. A 15-year review of porcelain veneer failure--a clinician's observations. *Compend Contin Educ Dent.* 1998 Jun;19(6):625-8
- Friedman MJ. A 15-year review of porcelain veneer failure--a clinician's observations. *Compend Contin Educ Dent.* 1998 Jun;19(6):625-8
- Gurel G, Bichacho N. Permanent diagnostic provisional restorations for predictable results when redesigning the smile. *Pract Proced Aesthet Dent.* 2006 Jun;18(5):281-6.
- Gurel G. Predictable, precise, and repeatable tooth preparation for porcelain laminate veneers. *Pract Proced Aesthet Dent.* 2003 Jan-Feb;15(1):17-24; quiz 26.
- Ibarra G, Johnson GH, Geurtsen W, et al. Microleakage of porcelain veneer restorations bonded to enamel and dentin with a new self-adhesive resin-based dental cement. *Dent Mater.* 2007 Feb;23(2):218-25.
- Lacy AM, Wada C, Du W, et al. In vitro microleakage at the gingival margin of porcelain and resin veneers. *J Prosthet Dent.* 1992 Jan;67(1):7-10.
- Magne P, Cascione D. Influence of post-etching cleaning and connecting porcelain on the microtensile bond strength of composite resin to feldspathic porcelain. *J Prosthet Dent* 2006;96:354-61.
- Magne P, Douglas W. Additive Contour of Porcelain Veneers: A Key Element in Enamel Preservation, Adhesion, and Esthetics for Aging Dentition. *J Adhesive Dent,* 1999,1 ,81 - 92
- Magne P, Douglas WH. Design optimization and evolution of bonded ceramics for the anterior dentition: a finite-element analysis. *Quintessence Int.* 1999 Oct;30(10):661-72.
- Magne P, Gallucci GO, Belser UC. Anatomic crown width/length ratios of unworn and worn maxillary teeth in white subjects. *J Prosthet Dent.* 2003 May;89(5):453-61.
- Magne P, Kwon KR, Belser UC, et al. WH. Crack propensity of porcelain laminate veneers: A simulated operator evaluation. *J Prosthet Dent.* 1999 Mar;81(3): incomplete reference
- Mizrahi B. Visualization before finalization: a predictable procedure for porcelain laminate veneers. *Pract Proced Aesthet Dent.* 2005 Sep;17(8):513-8.
- Peumans M, De Munck J, Fieuws S, Lambrechts P, Vanherle G, Van Meerbeek B. A prospective ten-year clinical trial of porcelain veneers. *J Adhes Dent.* 2004 Spring;6(1):65-76.
- Sarver DM. The importance of incisor positioning in the esthetic smile: the smile arc. *Am J Orthod Dentofacial Orthop.* 2001 Aug;120(2):98-111.
- Shen C, Oh WS, Williams JR. Effect of post-silanization drying on the bond strength of composite to ceramic. *J Prosthet Dent.* 2004 May;91(5):453-8.
- Tjan AH, Dunn JR, Sanderson IR. Microleakage patterns of porcelain and castable ceramic laminate veneers. *J Prosthet Dent.* 1989 Mar;61(3):276-82.
- Wise MD. Stability of gingival crest after surgery and before anterior crown placement. *J Prosthet Dent.* 1985 Jan;53(1):20-3.